



Diagnosis and management of common maxillofacial injuries in the emergency department. Part 4: orbital floor and midface fractures

P Ó Ceallaigh, K Ekanaykaee, C J Beirne and D W Patton

Emerg. Med. J. 2007;24:292-293
doi:10.1136/emj.2006.035964

Updated information and services can be found at:
<http://emj.bmj.com/cgi/content/full/24/4/292>

These include:

References

This article cites 3 articles, 1 of which can be accessed free at:
<http://emj.bmj.com/cgi/content/full/24/4/292#BIBL>

Rapid responses

You can respond to this article at:
<http://emj.bmj.com/cgi/eletter-submit/24/4/292>

Email alerting service

Receive free email alerts when new articles cite this article - sign up in the box at the top right corner of the article

Topic collections

Articles on similar topics can be found in the following collections
[Injury](#) (841 articles)

Notes

To order reprints of this article go to:
<http://www.bmjournals.com/cgi/reprintform>

To subscribe to *Emergency Medicine Journal* go to:
<http://www.bmjournals.com/subscriptions/>

MAXILLOFACIAL INJURY

Diagnosis and management of common maxillofacial injuries in the emergency department. Part 4: orbital floor and midface fractures

P Ó Ceallaigh, K Ekanayake, C J Beirne, D W Patton

Emerg Med J 2007;**24**:292–293. doi: 10.1136/emj.2006.035964

Beware of the black eye! Orbital injuries are often missed or misdiagnosed. The underlying bony injury and or globe injury are often more serious than initial examination suggests.

The hanging drop sign may be present in a floor of the orbit fracture but although it is suggestive of an orbital floor fracture it is not indicative. This sign is operator sensitive as some people may mistake the infra orbital foramen as the hanging drop.

If an orbital floor fracture is suspected, a computed tomography scan will confirm the diagnosis, with coronal and saggital slices giving the most information on the extent of the fracture.

Eyelid lacerations associated with facial trauma should not be underestimated and the eye should be evaluated thoroughly. This includes examination of the inner aspect of the lid to ensure that it is not a through and through laceration.

The diagnosis is initially a clinical one and is suggested by restriction of eye movement, with or without diplopia, or hypoglobus of the affected eye.

HISTORY

Inquire to the mechanisms of injury, the force involved, the presence of double vision, epistaxis, infra orbital parasthesia, pain on movement, or limited movement of the eye. New onset floaters are indicative of impending retinal detachment.

It is important to consider a retrobulbar haemorrhage, with an associated blow-in fracture of the orbit, in the patient with progressive visual loss.

CLINICAL EXAMINATION

Note oedema or ecchymosis and look for the presence of lacerations, epistaxis, ptosis, or hypertelorism

The eye must be examined. If the eyelid is swollen, retract the lids manually. If this cannot be done, check light perception by shining a torch through the closed lid. In a normal eye the patient will be able to appreciate light.

Note the extraocular movements and check for diplopia, ophthalmoplegia, hypoglobus (a horizontal line drawn between the medial canthi bilaterally should pass through the centre of each pupil; if one pupil is below to this plane, it is known as hypoglobus), enophthalmos (which may not be initially apparent), proptosis, pupillary size, and reaction to light both direct and consensual. Record the visual acuity. Test visual fields in each eye. Perform fundoscopy to assess any lens dislocation, vitreous haemorrhage, retinal detachment, and the presence of foreign bodies. Refer for an ophthalmological assessment if unsure of status of eye.

RADIOLOGICAL ASSESSMENT

Plain radiographic findings are often inadequate in orbital floor fractures. There may be an associated malar fracture and/or a fluid level in maxillary sinus.

INITIAL MANAGEMENT

Monitor vision regularly as progressive visual loss can occur rapidly.

The patient must be advised to avoid blowing their nose to prevent surgical emphysema or displacement of bony orbital floor fragments, which may impinge on the optic nerve.

Children with restricted eye movement, secondary mid face/orbital trauma must be referred immediately as they are at a high risk of necrosis of the entrapped ocular muscle. They require urgent release of the muscle in theatre.

RETROBULBAR HAEMORRHAGE

History: trauma to the eye or orbitozygomatic complex region with severe pain in the eye, and/or reduced eye movement (ophthalmoplegia), and/or reduced vision.

Examination: proptosis, progressive ophthalmoplegia, ptosis, decreasing visual acuity, sluggish dilated pupil. Fundoscopy reveals pallor or venous dilation of the disc.

Management: blindness is because of the haemorrhage pressure effect with resultant ischaemia of optic nerve. This is an acute surgical emergency requiring surgical decompression, but medical treatment may be employed to "buy time" until able to decompress surgically. Decompression should be immediate; if the delay in decompression is greater than two hours it will result in blindness.

Medical treatment includes mannitol intravenously (20% 200 mls), acetazolamide 500 mg intravenously, and dexamethasone 4 mg/kg bolus and 2 mg/kg six hourly for 24 hours

If in doubt call maxillofacial or ophthalmology immediately.

LE FORT FRACTURES

History

The patient is usually involved in a high velocity impact or vicious assault and may complain of altered occlusion.

See end of article for authors' affiliations

Correspondence to:
Padraig Ó Ceallaigh,
Maxillofacial Department,
Morrison Hospital,
Swansea, SA6 6NL, UK;
ppoceallaigh@hotmail.com

Accepted 8 April 2006

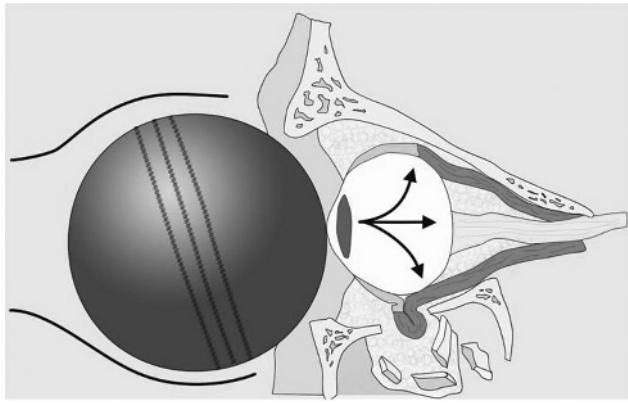


Figure 1 Mechanism of orbital floor fracture.

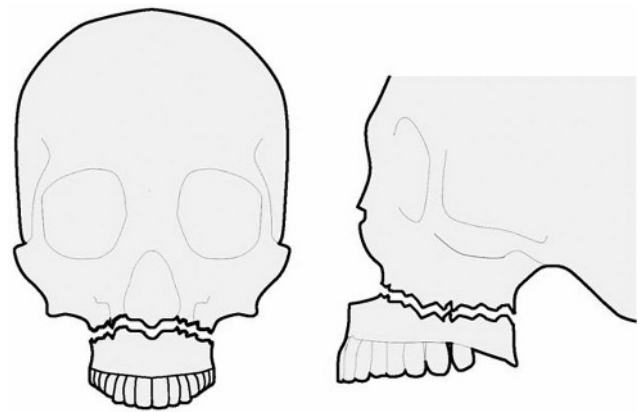


Figure 2 Le Fort I low level.

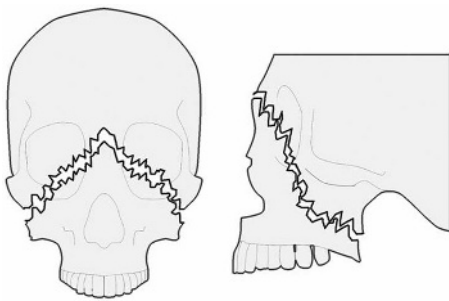


Figure 3 Le Fort II pyramidal, nasomaxillary.

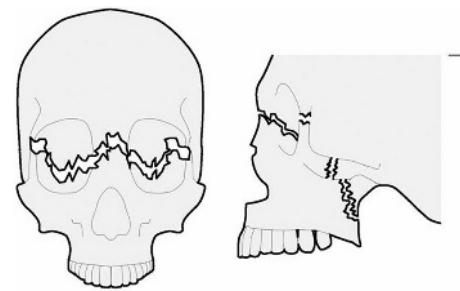


Figure 4 Le Fort III high level, craniofacial dysjunction.

Examination

Specifically noting the presence of panda facies, chemosis (oedema of conjunctiva), bilateral raccoon eyes, bruising over the mastoid process (battles sign), cerebrospinal fluid rhinorrhoea, cerebrospinal fluid otorrhoea, anterior open bite (whereby the patient is unable to close the teeth together anteriorly as the maxilla has slid posteriorly causing premature contact of the posterior teeth), posterior gagging, ecchymosis of the maxillary vestibule, palatal laceration, palatal split, palpable infra orbital step, mobile nasal bridge, tenderness over buttresses, and mobility of the maxilla. If the fracture is impacted mobility may not be a feature.

Examine the eye as previously described.

Radiological assessment

Plain films, including OPG, PA mandible, sub-mento vertex, and lateral skull, are of benefit. Fractures are identified as previously described.

A spiral computed tomography scan with axial and coronal and 3D reconstruction is the gold standard.

Management

Airway as previously described. Document all dental injuries. For unaccountable teeth do a chest x ray. Document facial soft tissue injuries.

Cerebrospinal fluid leak is common with Le Fort II and III fractures. Tramlining or ringing may occur with cerebrospinal fluid in the centre with a blood circle on the outside. The presence of beta 2-transferrin in the fluid is diagnostic.

Commence intravenous fluids, intravenous antibiotics, and analgesia. The patient should be kept nil by mouth and promptly referred to the maxillofacial service.

ACKNOWLEDGEMENTS

The authors would like to thank Simon Edwards, Medical Illustrator, Morrision Hospital, and Michelle and Ronan for their cooperation in the production of this article.

Authors' affiliations

K Ekanaykae, C J Beirne, Beaumont Hospital, Dublin, Eire
P Ó Ceallaigh, D W Patton, Morrision hospital, Swansea, Wales, UK

Competing interests: None.

Further Reading

- **Fonseca RJ**. Oral and maxillofacial surgery. Volume 3: trauma London: Saunders, 2000:205–44.
- **Gibbons AJ, Kittur MA, Dhariwal DK, et al**. A form for referral of injured patients between maxillofacial and ophthalmology units. *Br J Oral Maxillofac Surg* 2004;**42**(4):339–41.
- **Hayter JP, Sugar AW**. An orbital observation chart. *Br J Oral Maxillofac Surg* 1991;**29**(2):77–9.
- **Key SJ, Dhariwal DK, Patton DW**. Beware the black eye. *Trauma* 2002;**4**:237–245(9).